

Correlating Changes in QNE Scores to Quantified Changes in Hippocampal Surface Area and Volume in Huntington's Disease Patients

Shahrukh N. Bakar
Medical Image Analysis Laboratory
School of Engineering Science
Simon Fraser University
shahrukh_bakar@hotmail.com

Declines in hippocampal volume have been quantitatively observed in patients with Huntington's disease (HD) by Rosas *et al.* (2003). However, these declines, along with declines in hippocampal surface area, have not been considered with respect to changes in the severity of HD. *Objective:* To quantitatively describe and correlate changes in Quantified Neurologic Exam (QNE) scores to changes in hippocampal surface area and volume in HD patients. *Methods:* Hippocampal structures were manually segmented in temporally-separated MRI datasets of seven HD patients. Hippocampal surface areas and volumes were calculated. Inter-scan changes in these were plotted with changes in QNE scores for each patient. Surface meshes and contours were generated using these data. *Results:* Surface areas and volumes changed significantly between each pair of datasets for each HD patient. Clear correlations with changes in pairs of QNE scores have been observed. *Conclusions:* This study not only confirms statistically significant declines in hippocampal surface area and volume in patients with HD, but also quantitatively correlates them with respect to non-time-based progression of HD, as indicated by the *change* in pairs of QNE scores. The results may be useful in a clinical environment, where observed changes in an HD patient's QNE scores could be used to quantitatively estimate loss of hippocampal surface area and volume; particularly when multiple MRI datasets are not available.

Huntington's disease (HD) is a neurodegenerative genetic disease that causes atrophy in various regions of the brain; such as the caudates and putamen (Aylward *et al.*, 1997; Aylward *et al.*, 2004; Kassubek *et al.*, 2004; de la Monte *et al.*, 1988; Rosas *et al.*, 2001; Slow *et al.*, 2003). Hippocampal atrophy is especially detrimental to memory formation in advanced stages of HD, and can be used in clinicopathological assessments of the progression of the disease.

The severity of HD is tracked by rating a patient on the Quantified Neurologic Exam (QNE) score scale. This standardized scale assigns an overall numerical value from 0 to 129, depending on the degree of incoordination and/or chorea displayed during tasks performed in various sub-tests (Folstein *et al.*, 1983). A lower numerical value indicates fewer motor abnormalities. A large, positive change in inter-scan QNE scores indicates a large deterioration of

motor abilities.

Although Rosas *et al.* (2003) have observed large declines in hippocampal volume, changes in hippocampal surface area have not been quantified. Changes in surface area may be especially important to consider, since atrophy modes may not be uniform between hippocampal structures in various HD patients. It is widely believed that general HD symptoms are linked to a loss of hippocampal volume, but the link, if any, with the loss of surface area is unknown. The existence of a correlation between inter-scan changes in QNE scores and changes in hippocampal surface area and volume in patients with HD has not previously been investigated.

Even though the surface area and volume of the hippocampus are likely to change in different ways in patients, it would be especially useful in clinical practice to correlate changes in a patient's Quantified Neurologic Exam (QNE) score to the likely surface area and volume changes that have occurred. Such a correlation would provide additional support in diagnosis and would assist in tracking the progression of HD. Knowing the changes in hippocampal surface area and volume may also be useful in screening patients for recruitment in experimental drug or therapy protocols.

Methods

Segmentation of the Hippocampal Structures

Two MRI datasets ('snapshots') were obtained for each of the seven HD patients from Professor Elizabeth H. Aylward, University of Washington (Seattle, WA). Datasets were acquired on a General Electric 1.5 T scanner. Each dataset contained 124 2D image slices of the head in the axial, coronal and sagittal planes. For each dataset, the entire hippocampal structure was manually outlined by the author in 3D Slicer (image visualization and processing software), primarily in the sagittal plane. Differences in tissue density between the hippocampus and surrounding tissue, seen as the boundary between

light and dark areas in MRI slices, were used with expected anatomical location of the hippocampus as a criterion for defining the shape of the hippocampus. Three-dimensional Visualization ToolKit (VTK) virtual models were created from the outlines and volume and surface area statistics were computed by 3D Slicer from these. Segmentation was repeated eight times to improve the accuracy of data obtained.

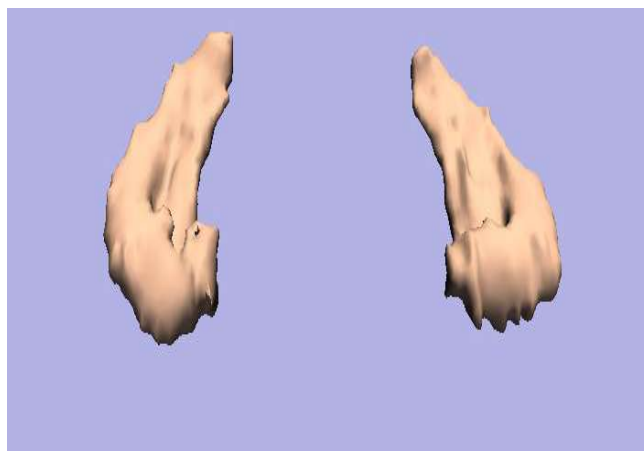


Fig. 1: Screenshot of typical 3D VTK virtual model of the hippocampal structures generated by Slicer.

Calculations

The Mean and 95% Confidence Interval were calculated from the eight hippocampus segmentations; for both surface area and volume in each dataset. This was performed once per dataset; therefore twice per patient. Each patient's inter-scan surface area and volume deltas were calculated by subtracting hippocampal surface area and volume means of the first snapshot from the respective surface area and volume means of the second snapshot. Combined surface area and volume 95% Confidence Intervals were generated from the two snapshots for each patient by adding together respective surface area and volume 95% Confidence Intervals from each scan.

Generation of Surface Meshes and Filled Contour Maps

Changes in the seven patients' hippocampal surface area were stored as a 1 x 7 string in Matlab. Similarly, changes in hippocampal

volume, and changes in the patients' QNE scores were also stored as 1 x 7 strings. The change in hippocampal surface area data were plotted as points along the x-axis; the change in hippocampal volume data were plotted as points in the y-axis, and the corresponding change in QNE score data were plotted as points in the z-axis. This produced a three dimensional scatter plot of seven points. Using this scatter plot, Matlab then generated a surface mesh using the 'mesh' feature, with a 'cubic' argument. Filled contour maps were generated using the 'contourf' feature, with steps in the change in QNE scores representing contour areas.

Results

Overall, each of the seven patients showed statistically significant declines in both surface area and volume of the hippocampus between scans, as shown by non-overlapping 95% confidence intervals for each parameter. (Figure 2)

For all seven patients, the loss of surface area and volume appears to be linked: even though the losses may vary in magnitude, they appear to follow a somewhat uniform 'slope'. This indicates similar modes of atrophy amongst all patients. The variation in the magnitudes of the losses may be due to different inter-scan time periods (mean inter-scan time period and S.D. are 3.1 years and 0.9 years, respectively), varying lengths of the unstable CAG repeat in the huntingtin gene on chromosome 4 (The Huntington's Disease Collaborative Research Group, 1993), and varying ages of the patients.

From Figure 2, the volume and surface area delta graph was generated, and is shown below.

By extending Figure 3 into three dimensions, Figure 4 was generated (below). Figure 4 shows the surface mesh and filled contour map generated by Matlab. The filled contour map is shown by itself in Figure 5 (below).

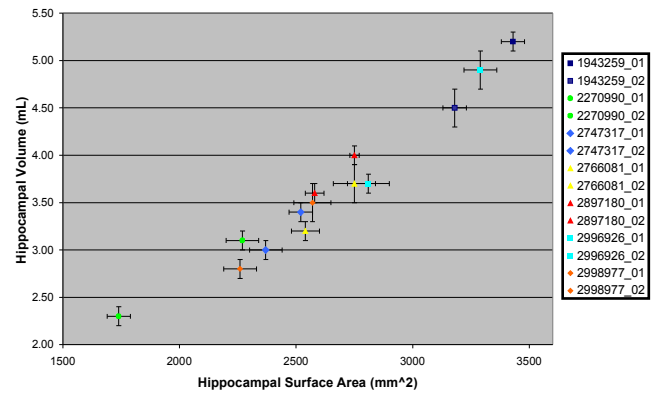


Fig. 2: Overview: Hippocampus Volume vs. Surface Area in Seven HD Patients. xxxxxxx_01 refers to first snapshot, xxxxxxx_02 refers to second snapshot. Bars represent 95% confidence intervals (n = 8 on both axes).

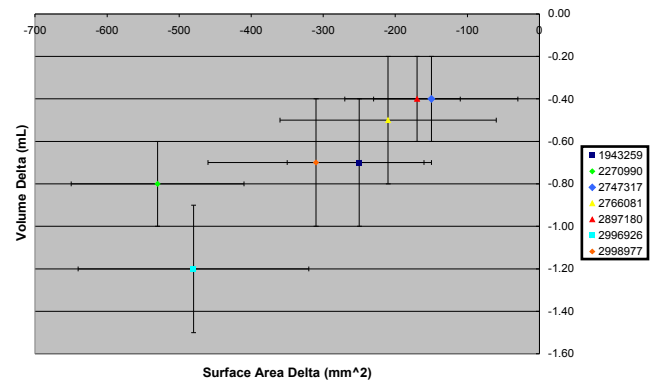


Fig. 3: Hippocampus Volume Delta vs. Surface Area Delta in Seven HD Patients. Bars represent combined 95% confidence intervals.

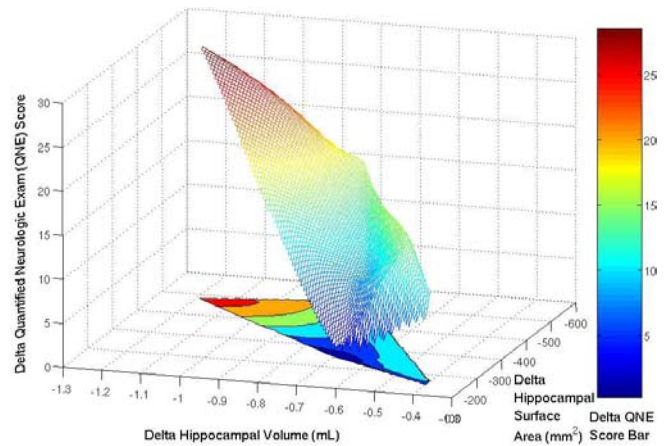


Fig. 4: Overview: Change in QNE Score versus Change in Hippocampal Volume versus Change in Hippocampal Surface Area Surface Mesh and Filled Contour Map for Seven HD Patients. Confidence interval bars have been omitted for clarity. Contour lines are 5 units apart.

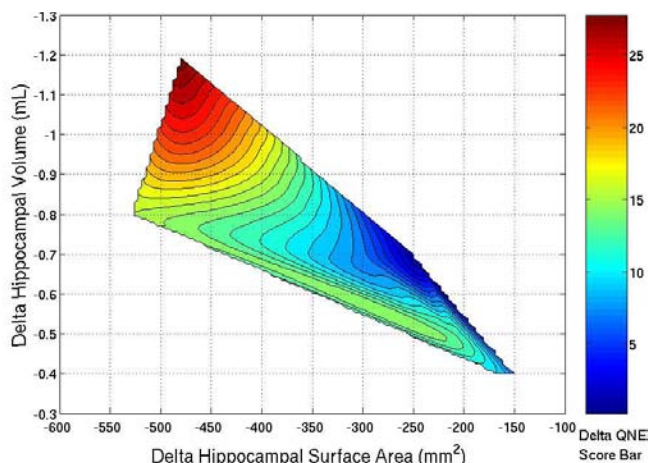


Fig. 6: Change in Hippocampal Volume versus Change in Hippocampal Surface Area Filled Contour Map. Changes in QNE Score values are indicated in steps of 1 unit by contour lines.

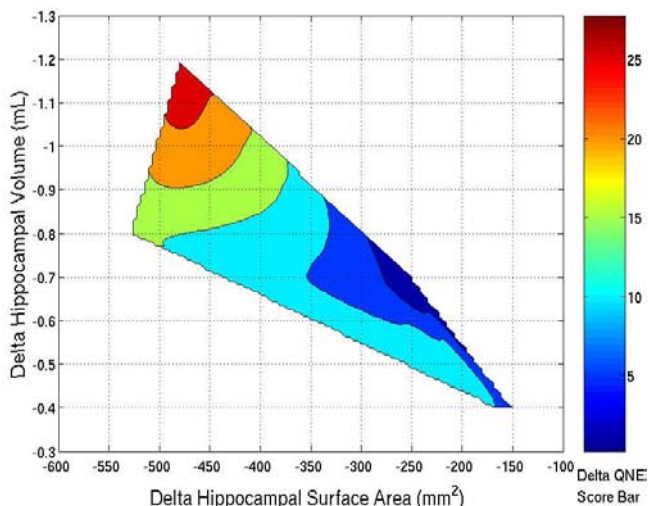


Fig. 5: Change in Hippocampal Volume versus Change in Hippocampal Surface Area Filled Contour Map. Changes in QNE Score values are indicated in steps of 5 units by contour lines.

Discussion

The severity of motor abnormalities (and, therefore, the severity of HD) has already been categorized as ‘mild’ and ‘moderate’; indicated by QNE scores of ≤ 35 and > 45 , respectively (Aylward *et al.*, 2004) However, to analyze the contour map generated in Figure 4, it is necessary to establish a *change* in QNE score severity scale. For this study, a *change* in QNE score of 0 thru 10

shall denote ‘mild change’; 11 thru 20 shall denote ‘moderate change’, and 21-30 shall signify ‘severe change’. It is important to note that this change in QNE score scale is not time-based, and cannot therefore be used as a standalone indicator of clinical progression of HD. However, a QNE score delta of, say, 10, in 2 years is clearly worse than the same score delta in 20 years.

It is now possible to quantify the estimated loss of hippocampal surface area and volume between two neurological exams of one patient. For example, if the patient has a mild inter-exam *change* in QNE score of 8, then the likely loss of hippocampal surface area and volume would be in the middle of the second-darkest blue zone in Figure 5. For clarity, Figure 5 has been further subdivided into change in QNE score steps of 1 (see Figure 6).

Clearly, a range of values must be given for both loss of hippocampus surface area and volume. For any given change in QNE score, the range of estimated loss for both surface area and volume is shown by the spread of values covered by the corresponding contour area. However, the most likely value is shown by the part of the contour area on which the longest line segment can be drawn, orthogonal to the parameter axis (see next paragraph and pink lines in Figure 6 above as examples).

The contour area for a change in QNE score of 8 is shown by the black arrow in Figure 6. This area shows a change in hippocampal surface area from about -325 mm^2 to -225 mm^2 , with the most likely change being about -310 mm^2 (vertical pink line, orthogonal to Delta Hippocampal Surface Area axis). Similarly, the change in hippocampal volume is shown from -0.85 mL to -0.58 mL , with the most likely change being around -0.67 mL (horizontal pink line, orthogonal to Delta Hippocampal Volume axis).

There is a particularly noteworthy feature shown in the contour areas in Figures 5 and 6. For example, a change in QNE score of 0 indicates an estimated change in surface area range from -260 mm^2 to -240 mm^2 , with the most likely value of

-250 mm², and a change in volume range from -0.75 mL to -0.65 mL, with the most likely value of -0.68 mL. This may be counter-intuitive, since no change in motor abnormalities may seem to indicate no change in hippocampal surface area and volume as well. However, Aylward et al. (2004) reported that striatal atrophy was present in patients with HD years before the disease was observed clinically. Even though the striatal structures do not include the hippocampus, the data in Figures 5 and 6 suggest that hippocampal atrophy exists before HD causes motor abnormalities that show up as a change in QNE score. This feature may be used to provide evidence for or against a clinical diagnosis of HD. For example, assume that a healthy person is diagnosed with HD based solely on the presence of a QNE score of, say, 10. An MRI scan is then performed, and the hippocampus is segmented out and compared with a segmentation from a previous MRI scan (at which time the QNE score was determined to be 0 or very low). If the patient has HD, then the contour area corresponding to a change in QNE score of 10 would show a change in hippocampal surface area and volume range that would encompass the observed changes. However, if large discrepancies are noted between the chart and the observed changes in hippocampal surface area or volume, then further examination, such as genetic testing for the length of the CAG repeat, a second opinion, or verification of the mode of atrophy, is warranted; possibly identifying an incorrect diagnosis or strengthening a correct one.

Knowing the likely changes in hippocampal surface area and volume may also aid in more rigorous screening of HD patients for experimental protocols or drug therapy trials requiring various levels of progression of HD.

This study is limited by various factors. For example, a small sample size of seven HD patients with multiple datasets limits the filled contour map's accuracy and area. This results in very large surface area and volume change ranges being indicated for a given change in QNE score

clinically observed. Also, patients with QNE score changes above 25 are not well represented on the contour map, resulting in misleading estimated hippocampal surface area and volume change ranges being generated. Extreme cases, with QNE score changes greater than 30 are not represented at all on the contour map. The small sample size also makes it impossible to tell whether more than one mode of hippocampal atrophy exists in patients with HD. More patients with multiple MRI datasets must be analyzed to improve the accuracy of the contour map, extend its application to severe and very severe cases, and possibly uncover other modes of hippocampal atrophy in patients with HD.

Another source of error is the lack of a completely objective system of defining the hippocampal structure boundaries in MRI slices. At present, a reliable, automated system for selecting and defining the hippocampus is not available. Therefore, segmentation of the hippocampus in MRI datasets had to be manually performed by the author. To help minimize error and variability, manual segmentation was repeated eight times per scan, and was performed by only the author. The development of computer-assisted recognition of the boundaries of the hippocampus in MRI images will undoubtedly increase accuracy and will allow for a greater number of HD patient datasets to be analyzed; while substantially reducing variability and cost at the same time.

In addition, the time period between scans has not been factored into the results or analysis. (In other words, the *rate* of change has not been accounted for; only the change itself has.) However, since the changes in QNE scores, changes in hippocampal surface area, and changes in hippocampal volume are not time-based (i.e. not 'changes per year'), it is unlikely that they would bias the results in any way.

It is also important to note that the pink lines in the filled contour area in Figure 6 do not represent 95% confidence interval ranges for the estimated changes in hippocampal surface area and volume.

Instead, they quantify the *most likely* changes expected for both surface area and volume. The range of possible changes (not necessarily a 95% confidence interval) for both parameters is indicated by the spread of values covered in each parameter by the section of contour area that corresponds to a given change in QNE score value.

Despite the limitations in this observational study, it is now possible to quantify the loss of hippocampal surface area and volume that has occurred in HD patients, from their inter-scan change in QNE score. This will undoubtedly help clinicians chart the progress of the disease and recommend treatment strategies that focus on the now-quantified hippocampal changes that cause HD symptoms; instead of administering treatment based entirely on the gut-level, intuitive and iterative 'wait-and-see' approach.

Acknowledgements

The author thanks Mirza Faisal Beg, director of the Medical Image Analysis Laboratory and professor of Engineering Science at Simon Fraser University, for allowing access to MRI datasets and lab equipment, supplying constructive criticism, and providing unyielding support; Elizabeth H. Aylward, professor of Radiology at the University of Washington (Seattle, WA), for supplying MRI datasets and QNE score statistics; Ali Khan for helping with organization of data and troubleshooting 3D Slicer, and this journal's anonymous referees for their valuable comments and suggestions. ■

References

- 3D Slicer. Version 2 (Linux). www.slicer.org.
- Aylward, E.H., Li, Q., Stine, O.C., Ranen, N., Sherr, M., Barta, P.E., et al. (1997). Longitudinal change in basal ganglia volume in patients with Huntington's disease. *Neurology*, 48, 394-399.
- Aylward, E.H., Sparks, B.F., Field, K.M., Yallapragada, V., Shpritz, O.D., Rosenblatt, A., et al. (2004). Onset and rate of striatal atrophy in preclinical Huntington disease. *Neurology*, 63, 66-72.
- Folstein, S.E., Jensen, B., Leigh, R.J., Folstein, M.F. (1983). The measurement of abnormal movement: methods developed for Huntington's disease. *Neurobehavior Toxicology and Teratology*, 5, 605-609.
- Kasubek, J., Juengling, F.D., Kioschies, T., Henkel, K., Karitzky, J., Kramer, B., et al. (2004). Topography of cerebral atrophy in early Huntington's disease: a voxel based morphometric MRI study. *Journal of Neurology Neurosurgery and Psychiatry*, 75, 213-220.
- de la Monte, S.M., Vonsattel, J.P., Richardson, E.P. Jr. (1988). Morphometric demonstration of atrophic changes in the cerebral cortex, white matter, and neostriatum in Huntington's disease. *Journal of Neuropathology and Experimental Neurology*, 47, 516-525.
- Rosas, H.D., Goodman, J., Chen, Y.I., Jenkins, B.G., Kennedy, D.N., Makris, N., et al. (2001). Striatal volume loss in HD as measured by MRI and the influence of CAG repeat. *Neurology*, 57, 1025-1028.
- Rosas, H.D., Koroshetz, W.J., Chen, Y.I., Skeuse, C., Vangel, M., Cudkovicz, M.E., et al. (2003). Evidence for more widespread cerebral pathology in early HD: an MRI-based morphometric analysis. *Neurology*, 60, 1615-1620.
- Slow, E.J., van Raamsdonk, J., Rogers, D., Coleman, S.H., Graham, R.K., Deng, Y., et al. (2003). Selective striatal neuronal loss in a YAC128 mouse model of Huntington disease. *Human Molecular Genetics*, 12, 1555-1567.
- The Huntington's Disease Collaborative Research Group. (1993). A novel gene containing a trinucleotide repeat that is expanded and unstable on Huntington's disease chromosomes. *Cell*, 72, 971-983.